



PRESENTING CLINICAL SIGNS

History: Grade 3/6 murmur. Radiographs revealed cardiomegaly. Pre-anesthetic evaluation (dental).

DATE

8/18/22

ECHOCARDIOGRAPHIC FINDINGS

2D, M-mode, and Doppler study.

PERFORMED BY:

Kelly Vazquez

INTERPRETED BY

Keith Blass, DVM,
MS, DACVIM
(Cardiology)

Left atrial size is normal. The mitral valve is normal. Left ventricular wall thickness is normal. Left ventricular internal dimensions are normal. Left ventricular systolic function is hyperdynamic. The aorta and aortic valve are normal. Right atrial and right ventricular dimensions are normal. The tricuspid valve is normal. The pulmonary artery and pulmonic valve are normal. No shunting lesions are visualized. No heartworms are visualized. No pericardial effusion or cardiac masses are seen.

PATIENT

Pumpkin Plasil

LA/Ao - 1.19
IVSd - 4.2 mm
LVPWd - 4.2 mm
LVIDd - 13.3 mm
LVIDs - 5.9 mm
FS - 55.6%
LVOT - 0.87 m/s
RVOT - 1.06 m/s

SPECIES

Feline

BREED

DSH

SEX

FS

ASSESSMENT/RECOMMENDATIONS

Normal echocardiogram

This examination demonstrates no evidence of structural heart disease. While a definitive reason for Pumpkin's murmur was not identified, it's likely that her murmur is functional/innocent in nature, as no flow abnormalities that could result in the development of a pathologic murmur were appreciated in the image set.

No therapy is recommended based on this exam, and there are no contraindications to the use of any specific anesthetic agents.

A recheck echocardiogram is recommended if the characteristics of Pumpkin's murmur change, or if other new physical exam and/or clinical abnormalities suggestive of cardiac dysfunction develop.

AGE

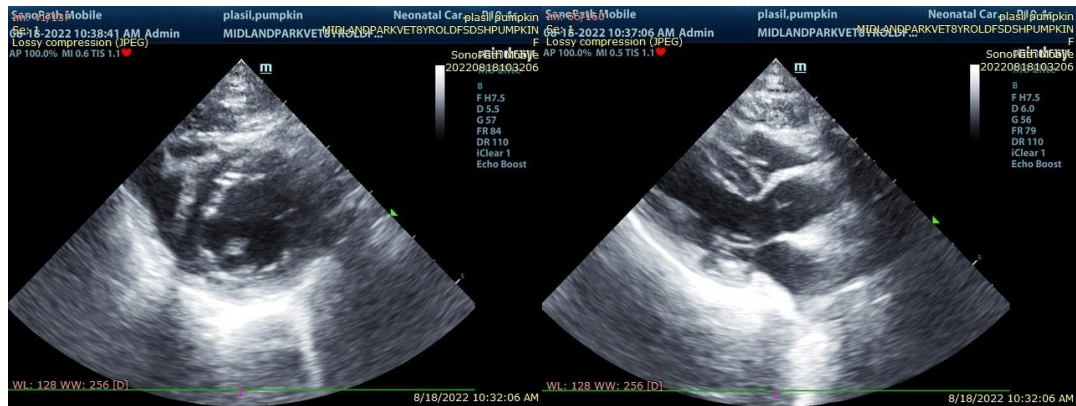
8 y

WEIGHT

11 lb

HOSPITAL NAME

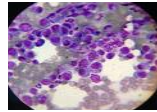
Midland Park VH



REFERRING VET

Dr. Shokoff

The information and recommendations provided are based on the images presented by the



referring veterinarian. No evaluation can be communicated regarding pathology that was not visible in the image/video clips provided.

DATE

8/18/22

Thank you for this referral. If the clinical or image interpretation does not parallel your findings or if I can be of any further assistance please contact me.

PERFORMED BY: Keith Blass, DVM, MS, DACVIM (Cardiology)

KeithBlass@gmail.com
631-804-5754

Kelly Vazquez

INTERPRETED BY

Keith Blass, DVM,
MS, DACVIM
(Cardiology)

PATIENT

Pumpkin Plasil

SPECIES

Feline

BREED

DSH

SEX

FS

AGE

8 y

WEIGHT

11 lb

HOSPITAL NAME

Midland Park VH

REFERRING VET

Dr. Shokoff